

Personal View

MANAGEMENT OF ACUTE FRACTURES AND NONUNIONS OF THE PROXIMAL POLE OF THE SCAPHOID

H. KRIMMER

From the Hand Center, Bad Neustadt, Germany

It is my belief that all acute proximal pole fractures should be treated by open reduction and internal fixation, via a dorsal approach. There is no longer any place for conservative treatment of these fractures, because a lengthy period of plaster immobilization is required and there is an unacceptably high risk of nonunion with conservative management. Unfortunately, nonunion of the proximal pole remains a common and disabling problem which demands careful evaluation and treatment. Internal fixation combined with limited cancellous bone grafting produces very satisfactory results in terms of pain relief and function, and clinical results are as good as those reported for more complex procedures involving vascularized grafts and prolonged cast immobilization. While the place for vascularized grafting has yet to be clearly defined, at present it is a technique which should be reserved for cases with long-standing ischaemia or failed previous surgery.

Journal of Hand Surgery (British and European Volume, 2002) 27B: 3: 245–248

INTRODUCTION

Although tradition has it that the majority of scaphoid fractures will heal uneventfully if adequately immobilized in plaster, the fact is that nonunion of the scaphoid remains a common and disabling problem. This is especially true for proximal pole fractures which, because of their precarious vascularity, have a particularly high rate of nonunion. The proximal pole relies mainly on retrograde blood flow from the scaphoid waist and distal pole for nourishment and fracture healing (Gelberman and Menon, 1980). As a consequence union may require 4–5 months of plaster cast immobilization and there is still a risk of nonunion. If nonunion occurs then avascular necrosis of the proximal pole frequently develops, requiring specific and time-consuming treatment. Proximal pole fractures are often missed because they are difficult to see on plain radiographs. Thus, when dealing with a possible scaphoid fracture, it is essential not only to identify these occult fractures but also to define their configuration. This is because, according to Herbert's classification, all proximal pole fractures (Type B3), whether displaced or undisplaced, should be regarded as unstable and treated surgically (Herbert, 1990)

Diagnosis of acute proximal pole fractures

Clinical symptoms are often minimal and a high index of suspicion is necessary. High quality radiographs should include (as a minimum) PA and lateral views with the wrist in neutral alignment, a PA view in full ulnar deviation (scaphoid view) and an oblique view in 45° pronation. If a fracture is suspected, but cannot be demonstrated on these initial radiographs, a CT scan should be ordered (Fig 1). Sagittal sections, taken at 0.5

or 1 mm intervals, which run parallel to the long axis of the scaphoid, are best for demonstrating fractures and any associated deformities (Krimmer et al., 2000). This technique requires the patient to lie prone in the scanner with his arm extended above the head. Precise positioning is essential, and reconstructions of axial CT scans of the wrist should not be used as an alternative, as they are of poor quality due to limited spatial resolution in the scan direction and motion artefacts. MRI (magnetic resonance imaging) is occasionally used to assess the vascularity of the proximal pole, but this is usually in cases of nonunion (Cerezal et al., 2000). MRI does not clearly show bony details and displacement of the fracture because of the limited image matrix (Kozin, 1997). Furthermore, bone marrow oedema, which is depicted by MRI with great sensitivity, might be due to either a bone contusion (so-called "bone bruise") which requires no treatment, or by a fracture which does require treatment.

Treatment of acute proximal pole fractures

Internal fixation should be regarded as the treatment of choice for all proximal pole fracture (Herbert, 1990; Rettig and Raskin, 1999). In contrast to fractures through the waist, which can be classified as stable or unstable according to the amount of displacement and the direction of the fracture line, all proximal pole fractures should be regarded as unstable, whether or not they are displaced, for the reasons mentioned above. It is essential that the fracture is completely immobilized in order to optimize the conditions for revascularization and healing. This is difficult, if not impossible, to achieve with external splintage alone, because there is no extrinsic ligamentous support around the proximal part

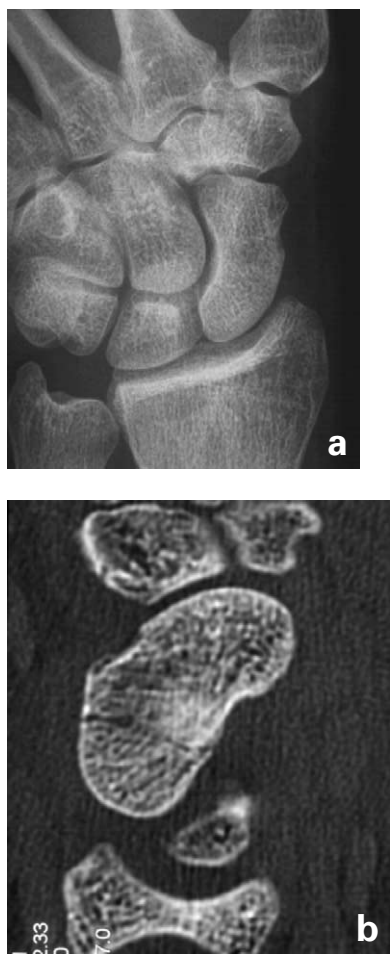


Fig 1 (a) Suspected fracture of the scaphoid. (b) Proximal pole fracture detected with CT scan.

of the scaphoid, which without doubt explains why proximal pole fractures have such high rates of nonunion.

Internal fixation is best carried out through a dorsal approach, using an intraosseous fixation device appropriate to the small size of the proximal fragment (Fig 2). The dorsal approach provides limited access with partial opening of the second and third extensor compartments and the wrist capsule over the scapholunate joint. It does not cause any further compromise to the blood supply of the proximal fragment and allows clear visualization of the fracture and exact placement of the screw (Rettig and Raskin, 1999). There is no real advantage to percutaneous insertion as no ligaments are incised with the open technique and the risk of incorrect positioning of the screw increases with the closed technique.

The mini-Herbert screw, which has a shank diameter of 1.5mm and small threads, can be easily inserted under direct vision into the small proximal fragment using a freehand technique. The small size of this screw minimizes the risk of displacement and disruption of the

small proximal fragment during fixation and allows the screw to be buried beneath the cartilage. The wrist is immobilized postoperatively for 2 weeks in a below-elbow cast and heavy manual activity is restricted during the first 6 weeks. Full activities are resumed once X-rays demonstrate fracture union. This treatment regime has a high success rate in our hands, even for proximal pole fractures which present up to 4 months following the injury.

Nonunion of fractures of the proximal pole

The situation has to be clearly defined when comparing different treatment strategies for nonunion in the proximal pole. Since vascularized bone grafts have gained popularity, assessment of avascularity of the proximal fragment based on preoperative MRI findings is frequently performed. It must be remembered that a precise assessment of vascularity with MRI can only be obtained if an intravenous contrast agent, gadopentate, is used. With this technique assessment of vascularity preoperatively may be useful (Cerezal et al., 2000). However it is a matter of concern that avascular necrosis (AVN) is often diagnosed by the presence of signal loss on plain T1 weight images. In my view, the term AVN should only be used when there is loss of bone stock, or even fragmentation due to longstanding avascularity. Signal loss in contrast MRI imaging and loss of punctuate bleeding intraoperatively should be used to indicate an avascular or ischaemic fragment rather than AVN (Gabl et al., 1999; Trumble, 1990). Similar terminology problems occur in Kienböck's disease, where complete signal loss on MRI, without disruption of the architecture of the lunate on plain radiographs, does not indicate complete avascular necrosis of the lunate, which would be in contradiction to the often observed recovery of such bone with conservative treatment.

Staging of proximal pole fracture nonunions

The classification of nonunions according to the Filan and Herbert system (Filan and Herbert, 1996) into D1 (fibrous nonunion), D2 (pseudarthrosis), D3 (sclerotic pseudarthrosis) and D4 (soft and fragmented bone) types helps one to decide on the most appropriate treatment. Good bone stock is a prerequisite for successful internal fixation, and fortunately this is usually excellent in types D1, D2 and D3. The proximal pole is only unsuitable for reconstruction when it is soft and fragmented due to avascular necrosis (Type D4). Under these circumstances one has to perform a primary salvage procedure. Fortunately, this problem is relatively rare, representing less than 10% of all proximal pole nonunions in our local personal series. Vascularity can be judged by MRI or by the presence of punctuate bleeding intraoperatively.

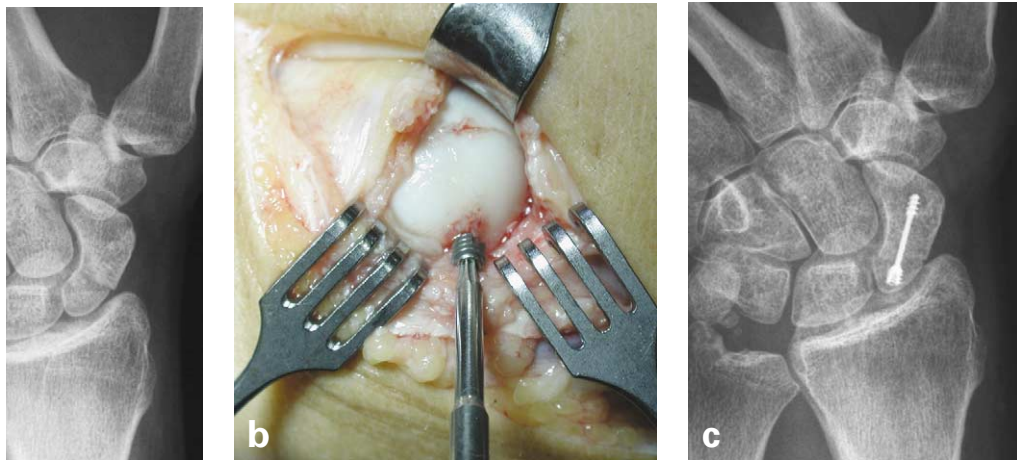


Fig 2 (a) Proximal pole fracture. (b) Intraoperative view of the dorsal approach with a mini Herbert screw inserted through the proximal pole. (c) X-ray view.

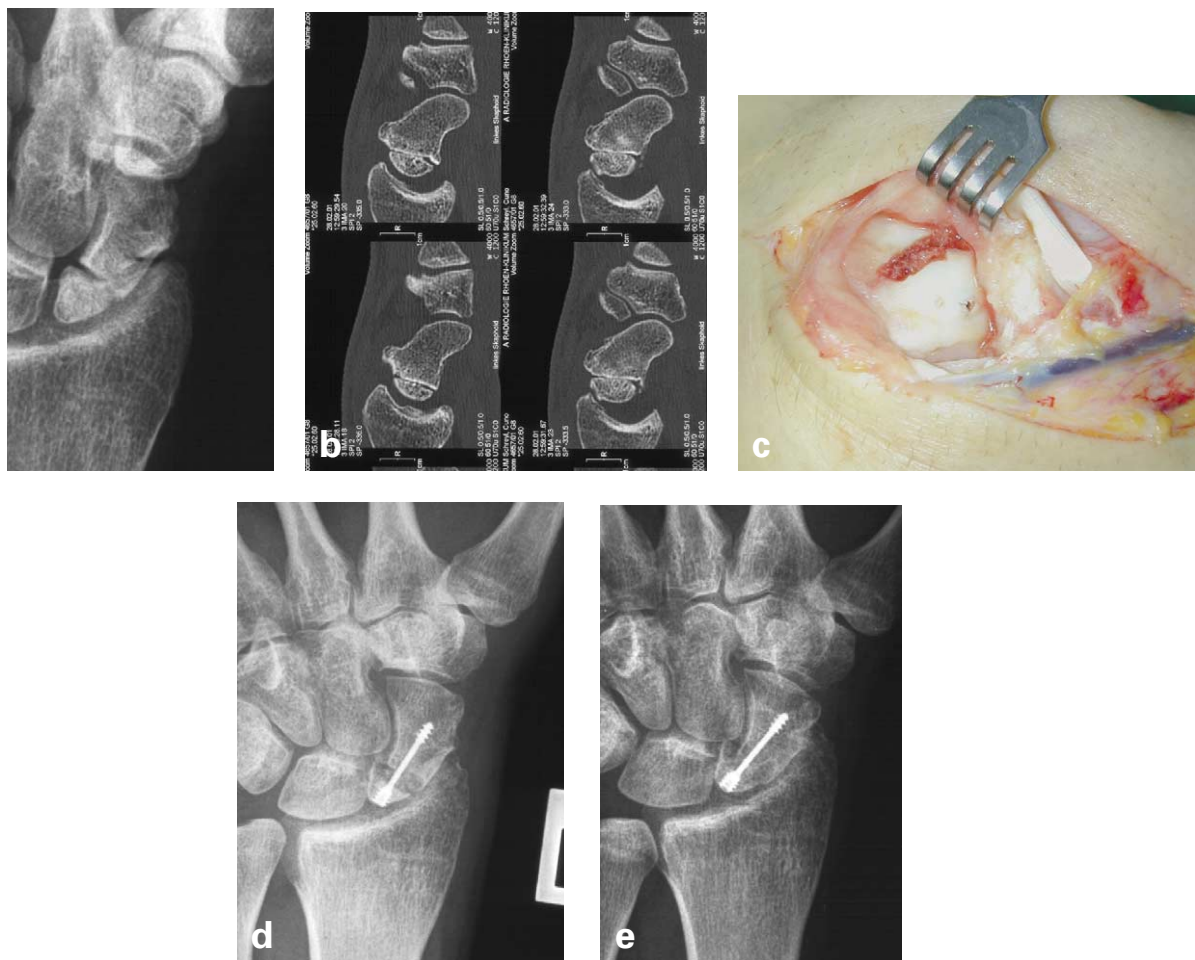


Fig 3 (a) Proximal pole nonunion. (b) Small proximal pole fragment demonstrated by CT scan. (c) Intraoperative view of reconstruction with a cancellous bone graft from the iliac crest and internal fixation with a mini Herbert screw. (d) Postoperative X-ray. (e) Bony union at 6 months follow-up.

Treatment of proximal pole fracture nonunions

The prognosis for union following reconstruction with internal fixation depends on the vascularity of the proximal pole, the duration of the nonunion and the stability of the fixation. The operation itself should not cause any further compromise to the blood supply, and we believe that a limited dorsal approach with internal fixation using the mini-Herbert screw is the most appropriate technique. In type D1 cases the fracture site is disturbed as little as possible and the two fragments are not separated. A small window is made at the fracture site and any fibrous tissue is removed. The defect is then packed with cancellous bone from the radius (Krimmer et al., 1999). In types D2 and D3, the fragments should be curetted until punctuate bleeding, or at least cancellous bone, is apparent. A cancellous bone block from the iliac crest is then interposed in the nonunion (Fig 3). This treatment strategy can still be used if there is avascularity of the proximal fragment, provided it is the first operation and it is within 1 year of the initial fracture. In cases of long-standing nonunion with loss of punctuate bleeding, or cases of failed previous surgery, vascularized bone grafts are preferable. If possible, we like to use the technique originally described by Zaidenberg et al. (1991), which was later anatomically refined by Sheetz et al. (1995). This utilizes a pedicled bone graft from the distal radius. Even when using a vascularized bone graft, we stabilize the fracture with a mini-Herbert screw whenever possible, or alternatively with two K-wires.

Reconstruction is usually impossible for type D4 nonunions, and one is left to decide which of the available salvage procedures is the most appropriate. Where symptoms demand it, my preference is to excise the proximal fragments if there are no signs of carpal collapse. Prosthetic replacement of the proximal pole does not strengthen or stabilize the proximal carpal row and should be abandoned due to the inherent disadvantages of this procedure, such as silicon synovitis (Carter et al., 1986; Haussmann, 1999). If carpal collapse is present, complete excision of the scaphoid with a four-corner fusion is my preferred treatment (Krimmer et al., 1992).

In our recently published series of 26 patients with proximal pole nonunion (Types D1–3) we were able to achieve a union rate of 74% using the technique described above, namely limited cancellous bone grafting combined with internal fixation using a mini-Herbert screw (Krimmer et al., 1999). Of the remaining patients, four had stable nonunions which only caused slight discomfort. Two patients had symptomatic nonunions, with loss of fixation, and both of these underwent a four-corner fusion with complete excision of the scaphoid. These results are similar to those reported by Herbert and Filan (1999), who in a larger series of patients had an 85% clinical success rate, even though only 50% of their fractures went on to sound bony

union. It is interesting to note that six patients in our local series had a proximal pole fragment that was judged to be completely avascular, but was not fragmented. These were all treated with standard cancellous bone grafting and internal fixation, and four of the six united. The reported union rates following vascularized bone grafting of proximal pole nonunions (Boyer et al., 1998; Gabl et al., 1999) are comparable to those we have been able to achieve with this much simpler technique. We continue to reserve vascularized grafting for selected cases which have either undergone long-standing ischaemia or failed previous surgery.

References

- Boyer MI, von Schroeder HP, Axelrod TS (1998). Scaphoid nonunion with avascular necrosis of the proximal pole. Treatment with a vascularized bone graft from the dorsum of the distal radius. *Journal of Hand Surgery*, 23B: 686–690.
- Carter PR, Benton LJ, Dysert PA (1986). Silicone rubber carpal implants: a study of the incidence of late osseous complications. *Journal of Hand Surgery*, 11A: 639–644.
- Cerezal L, Abascal F, Canga A et al. (2000). Usefulness of gadolinium-enhanced MR imaging in the evaluation of the vascularity of scaphoid nonunions. *American Journal of Roentgenology*, 174: 141–149.
- Filan SL, Herbert TJ (1996). Herbert screw fixation of scaphoid fractures. *Journal of Bone and Joint Surgery*, 78B: 519–529.
- Gabl M, Reinhart C, Lutz M et al. (1999). Vascularized bone graft from the iliac crest for the treatment of nonunion of the proximal part of the scaphoid with an avascular fragment. *Journal of Bone and Joint Surgery*, 81A: 1414–1428.
- Gelberman RH, Menon J (1980). The vascularity of the scaphoid bone. *Journal of Hand Surgery*, 5A: 508–513.
- Haussmann P (1999). Long-term outcome of partial alloplastic replacement of the scaphoid bone. *Handchirurgie Mikrochirurgie Plastische Chirurgie*, 31: 200–206.
- Herbert TJ. *The Fractured Scaphoid*. St. Louis, Quality Medical Publishing, 1990: 57.
- Herbert TJ, Filan SL (1999). Proximal scaphoid nonunion-osteosynthesis. *Handchirurgie Mikrochirurgie Plastische Chirurgie*, 31: 169–173.
- Kozin SH (1997). Internal fixation of scaphoid fractures. *Hand Clinics*, 13: 573–586.
- Krimmer H, Sauerbier M, Vispo-Seara JL et al. (1992). Advanced carpal collapse (SLAC-wrist) in scaphoid pseudarthrosis. Therapy concept: medio-carpal partial arthrodesis. *Handchirurgie Mikrochirurgie Plastische Chirurgie*, 24: 191–198.
- Krimmer H, Kremling E, van Schoonhoven J et al. (1999). Proximal scaphoid pseudarthrosis – reconstruction by dorsal bone screw and spongiosa transplantation. *Handchirurgie Mikrochirurgie Plastische Chirurgie*, 31: 174–177.
- Krimmer H, Schmitt R, Herbert T (2000). Scaphoid fractures – diagnosis, classification and therapy. *Unfallchirurg*, 103: 812–819.
- Rettig ME, Raskin KB (1999). Retrograde compression screw fixation of acute proximal pole scaphoid fractures. *Journal of Hand Surgery*, 24A: 1206–1210.
- Sheetz KK, Bishop AT, Berger RA (1995). The arterial blood supply of the distal radius and ulna and its potential use in vascularized pedicled bone grafts. *Journal of Hand Surgery*, 20A: 902–914.
- Trumble TE (1990). Avascular necrosis after scaphoid fracture: a correlation of magnetic resonance imaging and histology. *Journal of Hand Surgery*, 15A: 557–564.
- Zaidenberg C, Siebert JW, Angrigiani C (1991). A new vascularized bone graft for scaphoid nonunion. *Journal of Hand Surgery*, 16A: 474–478.

Received: 6 September 2001

Accepted after revision: 28 November 2001

Dr. Hermann Krimmer, Klinik für Handchirurgie, Rhoen-Klinikum AG, Salzburger Leite 1, D-97616 Bad Neustadt, Germany.

E-mail: kfh1.krimmer@handchirurgie.de

© 2002 The British Society for Surgery of the Hand

doi: 10.1054/jhsb.2001.0736, available online at <http://www.idealibrary.com> on IDEAL®